Saint-Petersburg
Centre of Multiple Sclerosis

Leptomeningeal contrast enhancement is associated with atrophy of subcortical structures in multiple sclerosis: longitudinal study

I. Kalinin, G. Makshakov and E. Evdoshenko
Saint-Petersburg Centre of Multiple Sclerosis and other autoimmune disease, Saint-Petersburg, Russian Federation

Background and aims

Leptomeningeal contrast enhancement (LMCE) in multiple sclerosis (MS) is a possible biomarker of neurodegeneration. We aimed to study the association between LMCE and atrophy of subcortical structures in MS.

Methods

42 MS patients (23 females, 19 males) were included. 3 Tesla MRI was performed on baseline and after 2 years.

LMCE were detected with post-contrast fluid attenuated inversion-recovery (FLAIR) sequence, 10 minutes after gadolinium administration. Intracranial volume (ICV), subcortical gray matter volume (sGMV), thalamus volume (TV), caudate volume (CV), putamen volume (PV) and pallidum volume (PaV) were calculated using FreeSurfer and presented as percent of ICV (% ICV). Age at baseline was assessed.

A Wilcoxon matched pairs test and analysis of covariance (ANCOVA) were conducted to determine statistically significant changes in subcortical volumes and an effect of LMCE on subcortical structures atrophy, respectively.

Results

LMCE-negative patients had a statistically significant atrophy of subcortical gray matter, thalamus, and caudate volume at follow-up.

LMCE-positive patients had a statistically significant atrophy of putamen. There were no significant changes of pallidum volume in both groups.

Results are shown in the Table 1.

There was a significant effect of LMCE-status on volume of thalamus (F=20.2, p=0.00007) and putamen (F=18.4, p=0.0001) after controlling for age and sex. All other measurements found no significant effect of LMCE.

Table 1. Subcortical structures volume change according to the LMCE-status

	LMCE-negative patients (n = 28)		LMCE-positive patients (n = 14)	
	Mean volume change (CI), %ICV	p	Mean volume change (CI), %ICV	p
Subcortical grey matter	-0.07 (-0.12; -0.02)	**0.016**	-0.04 (-0.1; 0.006)	0.06
Thalamus	-0.06 (-0.08; -0.03)	**0.0005**	0.02 (-0.02; 0.06)	0.27
Caudate	-0.02 (-0.03; -0.007)	**0.003**	-0.004 (-0.03; 0.02)	0.64
Putamen	-0.007 (-0.02; 0.008)	0.32	-0.07 (-0.1; -0.04)	**0.003**
Pallidum	-0.009 (-0.02; 0.002)	0.10	-0.007 (-0.02; 0.01)	0.55

LMCE - leptomeningel contrast enchancment, CI - confidence interval, ICV - intracranial volume,

Figure 1. Thalamus and putamen volume change according to the LMCE-status

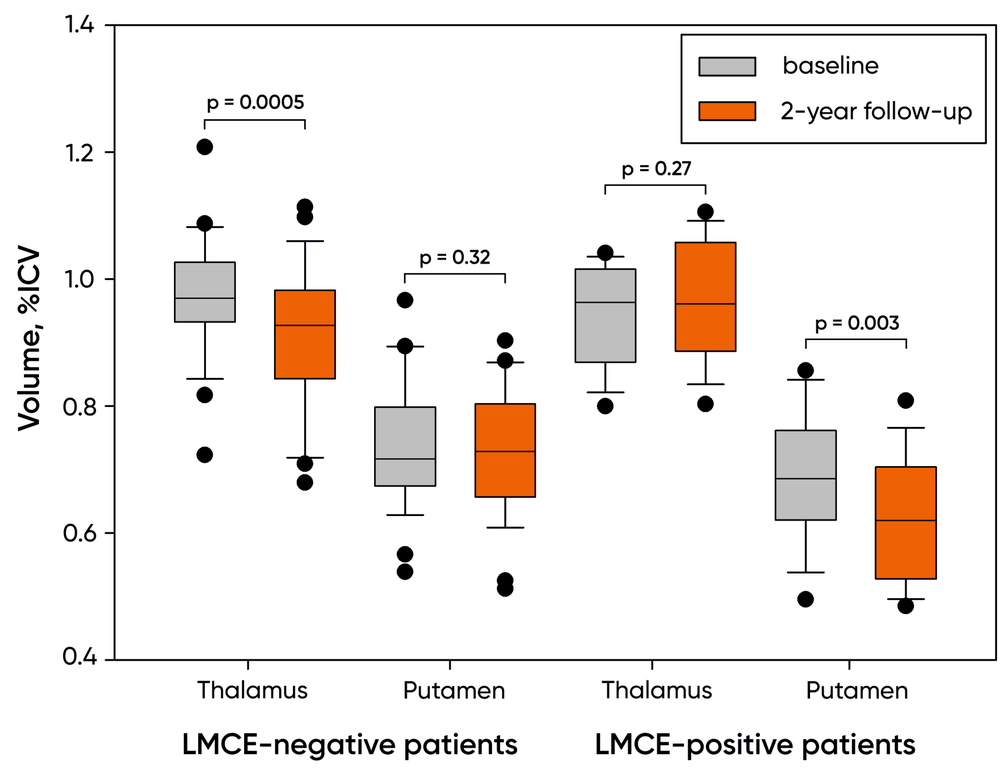

Plots the median, 10th, 25th, 75th and 90th percentiles as vertical boxes with error bars. ICV - intracranial volume, LMCE - leptomeningel contrast enchancment

Conclusion

LMCE-negative patients had thalamic atrophy, while LMCE-positive patients had putamen atrophy after 2 years. Thalamic and putamen atrophy were explained better by LMCE-status, than by age and sex. Possibly, that the presence of LMCE may reflect a distinct neurodegenerative process regarding subcortical structures.

Disclosure: Ivan Kalinin: nothing to declare; Gleb Makshakov has received honoraria for lectures and speaking in the past 2 years from Genzyme, Jansen and Roche; Evgeniy Evdoshenko has received honoraria for lectures and speaking in the past 2 years from Merck, Biogen, Roche, Johnson & Johnson, Novartis, GlaxoSmithKline, Sanofi, Genzyme, Generium.

Correspondence:
i.kalinin@centrems.com